

I Only Turned My Back for One Second!! Most Common Pediatric Toxicological Emergencies Seen Today

Michael Schill III, DNP, FNP-BC, ENP-C, CEN, CFRN, MICN
Lead EM APC- ApolloMD
St. Joseph's Health- New Jersey



Disclosures

I have no actual or potential conflict of interest in relation to this program/presentation.

Objectives

- Discuss the epidemiology of household ingestions in the pediatric population.
- Describe evaluation and management of potentially fatal ingestion of a single prescription medication.
- Identify common non-toxic toys that can still be toxic to the pediatric population.



2,080,659

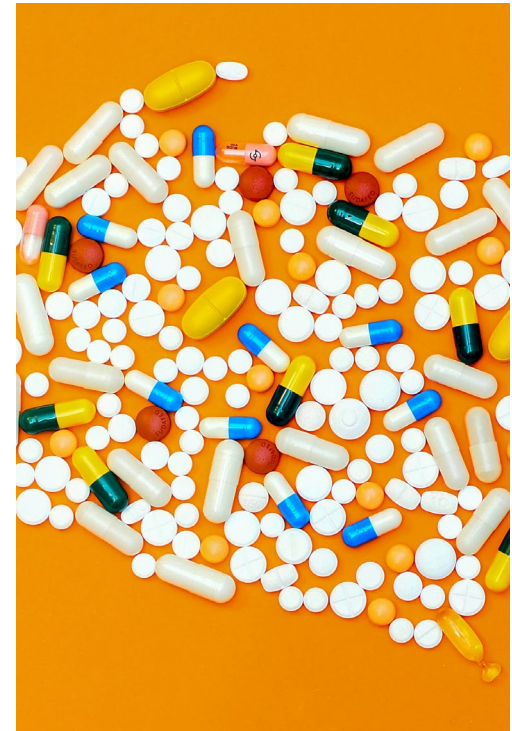Calls were placed
between all 55 National
Poison Control hotlines in
2023¹

Epidemiology

Ages 1-5- cleaning substances, Analgesics & Personal care products

Ages 6-12- Analgesics, Antihistamines, Foreign Body

Ages 13-19- Analgesics, Antidepressants, Antihistamines



Epidemiology



WHY ARE THERE THE
INCREASING NUMBER OF
CALLS?



IS THERE NEW
LEGISLATION?



ARE CHILDREN MORE
INTRIGUED?



Case One

15-month old male presents to the Urgent Care with the complaint of increasing cough, crying, and possible foreign body ingestion. He is accompanied by his mother who reports that she left him in the living room for one minute when she started to hear the patient coughing forceable. Mom reports that she found a drone remote control by the patient but did not witness him ingest anything.

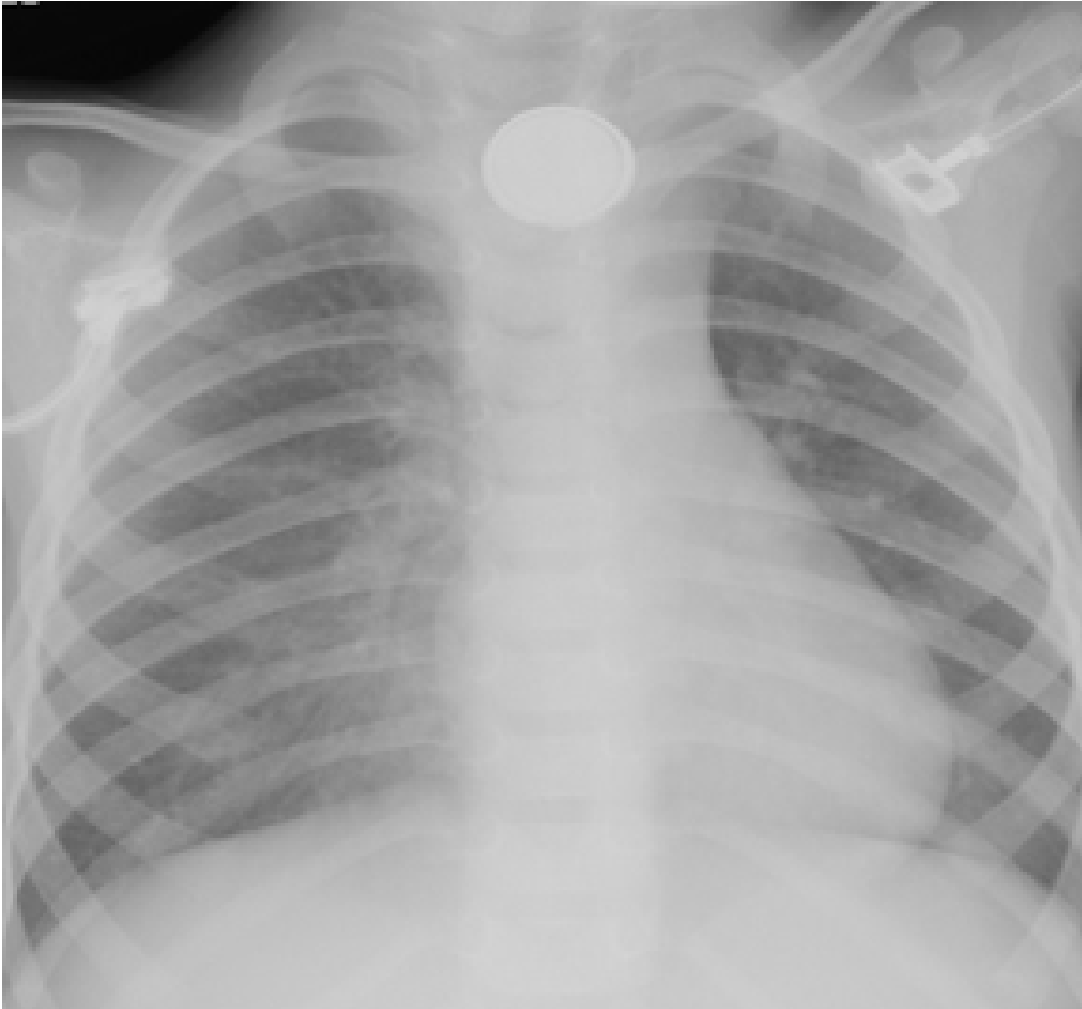


What questions do we want to ask?

From the door assessment components?



Vital Signs: Temp: 36.8°C, HR:
136 bpm, RR: 32 bpm, 97%
RA



Diagnosis:

Button Battery Ingestion

Button Battery Ingestion

Found in toys & small electronic with new lithium battery being more dangerous

Tissue is damaged by liquefactive necrosis from the negative pole

Can occur within 2 hours of ingestion



Management

- Lateral X-Ray
- Honey or Carafate q-10 mins
- Transfer to definitive care for GI services



Common other FB

Coins

Magnets

Legos

Beads

Marbles

Sharp Objects



Case Two

2-year-old female brought into the local community ED by EMS for increased lethargy. The patient is accompanied by her father who stated that the child was in her 22-year-old sister's room when he heard a noise. He reports that the patient had a bag of sour gummy worms by her side and chocolate, so he brought the bag with him. EMS report that they looked at the bags and noticed them to be THC gummies and chocolate with each piece containing 100 mg of THC per piece.

What questions do we want to ask?

From the door assessment components?



Vital Signs: Temp: 37.2°C, HR:
156 bpm, RR: 34 bpm, 93%
RA

Weight: 11 kg

THC Overdose Management

- Blood Work
- Urine Drug Screen
- Radiographic Imaging
- EKG
- IVF Bolus and Maintenance
- Airway Management
- Seizure prevention/treatment
- Transfer to Pediatric Center

Case Three

5-year-old male brought in by EMS with the complaint of an accidentally ingestion of his grandmother's medication. The patient's mother reports that he has been overly tired for the last three hours after taking a small white pill. EMS report that the patient's vital signs were all within normal limits except that his blood sugar was 70 mg/dL. The patient's mother reports that the grandmother takes medication for hypertension, hyperlipidemia, diabetes, and GERD.

What questions do we want to ask?

From the door assessment components?

Grandma's Pill Case



Calcium Channel
Blockers & Beta
Blockers

Opioids

Clonidine

Sulfonylureas

Cyclic
Antidepressants

Top Five Medications

Evaluation

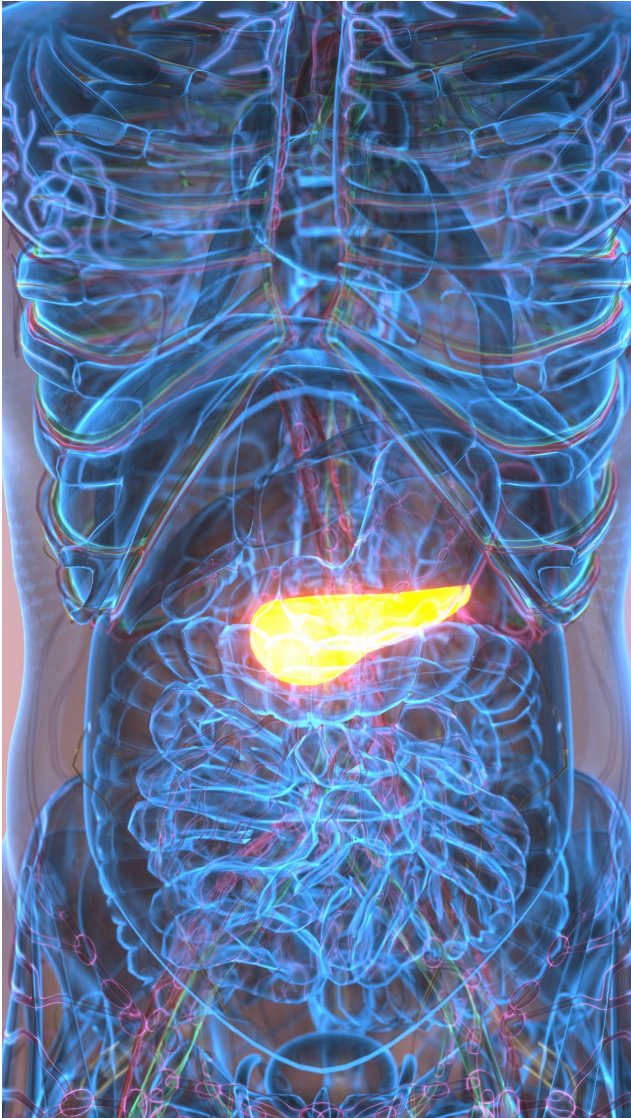
At the door assessment

POC blood glucose

Blood work

EKG

Treatment Plan



Sulfonylureas

- Used to Treat Type II Diabetes
- Long half life (24 hrs)
- Small dose can cause issues
- Difficult to Diagnose in Pediatric Population
- Admission for observation and frequent POC & Lab Tests



Other Potentials

- Beta Blockers
- Calcium Channel Blockers
- Tricyclic Antidepressants

Wrap Up

- Children are little magicians
- No cookie cutter treatment for foreign bodies
- Honey can be a life saver
- One Pill can actually cause major damage
- Remind parents and grandparents about drug safety

References

Burrows, K., & Williams, J. A. (2019). THC intoxication in a 16-month-old child. *Paediatrics & Child Health*, 24(5), 299-300. <https://doi.org/10.1093/pch/pxz015>

Foreign body ingestion — Button battery ingestion confirmed by X-ray — Clinical pathway: Emergency, ICU and inpatient. (2023, December 4). Children's Hospital of Philadelphia. Retrieved December 22, 2024, from <https://pathways.chop.edu/clinical-pathway/foreign-body-ingestion-button-battery-ingestion-confirmed-x-ray#esophagus>

Gummin, D. D., Mowry, J. B., Beuhler, M. C., Spyker, D. A., Rivers, L. J., Feldman, R., Brown, K., Pham, N. P., Bronstein, A. C., & DesLauriers, C. (2024). 2023 annual report of the national poison data system® (NPDS) from America's poison centers®: 41st annual report. *Clinical Toxicology*, 1-35. <https://doi.org/10.1080/15563650.2024.2412423>

Health routine control: senior woman hand putting pill capsules from the box to a weekly dose organizer. stock photo. . (2024, March 28). iStock/Alex

Potemkin. [https://www.istockphoto.com/photo/health-routine-control-senior-woman-hand-putting-pill-capsules-from-the-box-to-a-gm2118272364-](https://www.istockphoto.com/photo/health-routine-control-senior-woman-hand-putting-pill-capsules-from-the-box-to-a-gm2118272364-567367491?utm_campaign=srp_photos_bottom&utm_content=https%3A%2F%2Funsplash.com%2Fs%2Fphotos%2Fpill-case&utm_medium=affiliate&utm_source=unsplash&utm_term=pill+case%3A%3A%3A)

[567367491?utm_campaign=srp_photos_bottom&utm_content=https%3A%2F%2Funsplash.com%2Fs%2Fphotos%2Fpill-](https://www.istockphoto.com/photo/health-routine-control-senior-woman-hand-putting-pill-capsules-from-the-box-to-a-gm2118272364-567367491?utm_campaign=srp_photos_bottom&utm_content=https%3A%2F%2Funsplash.com%2Fs%2Fphotos%2Fpill-case&utm_medium=affiliate&utm_source=unsplash&utm_term=pill+case%3A%3A%3A)

[case&utm_medium=affiliate&utm_source=unsplash&utm_term=pill+case%3A%3A%3A](https://www.istockphoto.com/photo/health-routine-control-senior-woman-hand-putting-pill-capsules-from-the-box-to-a-gm2118272364-567367491?utm_campaign=srp_photos_bottom&utm_content=https%3A%2F%2Funsplash.com%2Fs%2Fphotos%2Fpill-case&utm_medium=affiliate&utm_source=unsplash&utm_term=pill+case%3A%3A%3A)

Hendron, D., Menagh, G., Sandilands, E. A., & Scullion, D. (2011). Tricyclic antidepressant overdose in a toddler treated with intravenous lipid emulsion. *Pediatrics*, 128(6), e1628-e1632. <https://doi.org/10.1542/peds.2011-0867>

Kumar, A. (2023, March 14). *Button battery ingestion | Radiology case | Radiopaedia.org*. Radiopaedia. <https://radiopaedia.org/cases/button-battery-ingestion-3?lang=us>

Pancreas, human digestive system illustration stock photo. (2023, January 31). iStock/XH4D. [https://www.istockphoto.com/photo/pancreas-human-digestive-system-](https://www.istockphoto.com/photo/pancreas-human-digestive-system-illustration-gm1460926309-495005942?utm_campaign=srp_photos_top&utm_content=https%3A%2F%2Funsplash.com%2Fs%2Fphotos%2Fpancreas&utm_medium=affiliate&utm_source=unsplash&utm_term=pancreas%3A%3A%3A)

[illustration-gm1460926309-](https://www.istockphoto.com/photo/pancreas-human-digestive-system-illustration-gm1460926309-495005942?utm_campaign=srp_photos_top&utm_content=https%3A%2F%2Funsplash.com%2Fs%2Fphotos%2Fpancreas&utm_medium=affiliate&utm_source=unsplash&utm_term=pancreas%3A%3A%3A)

[495005942?utm_campaign=srp_photos_top&utm_content=https%3A%2F%2Funsplash.com%2Fs%2Fphotos%2Fpancreas&utm_medium=affiliate&utm_source=unsplash&utm_term=pancreas%3A%3A%3A](https://www.istockphoto.com/photo/pancreas-human-digestive-system-illustration-gm1460926309-495005942?utm_campaign=srp_photos_top&utm_content=https%3A%2F%2Funsplash.com%2Fs%2Fphotos%2Fpancreas&utm_medium=affiliate&utm_source=unsplash&utm_term=pancreas%3A%3A%3A)

Pepin, L. C., Simon, M. W., Banerji, S., Leonard, J., Hoyte, C. O., & Wang, G. S. (2023). Toxic tetrahydrocannabinol (THC) dose in pediatric cannabis edible ingestions. *Pediatrics*, 152(3). <https://doi.org/10.1542/peds.2023-061374>

Sheridan, D. C., Hughes, A., & Horowitz, B. Z. (2021). Pediatric ingestions: New high-risk household hazards. *Pediatrics In Review*, 42(1), 2-10. <https://doi.org/10.1542/pir.2019-0309>

Tørisen, T. A., Glanville, J. M., Loaiza, A. F., & Bidonde, J. (2024). Emergency pediatric patients and use of the pediatric assessment triangle tool (PAT): A scoping review. *BMC Emergency Medicine*, 24(1). <https://doi.org/10.1186/s12873-024-01068-w>

Unsplash. (2018, December 28). *Photo by Luz Fuertes on Unsplash*. Beautiful Free Images & Pictures |

Unsplash. <https://unsplash.com/photos/boy-wearing-black-crew-neck-shirt-3GG4DpwMNk8>

Unsplash. (2018, August 7). *Photo by bill Craighead on Unsplash*. Beautiful Free Images & Pictures |

Unsplash. <https://unsplash.com/photos/jelly-tube-lot-lpJ5j4ox9BE>

Unsplash. (2019, April 12). *Photo by Mae Mu on Unsplash*. Beautiful Free Images & Pictures |

Unsplash. <https://unsplash.com/photos/brown-wooden-shower-head-Mqb0YDRNr7k>

Unsplash. (2019, January 10). *Photo by Jonathan J. Castellon on Unsplash*. Beautiful Free Images & Pictures |

Unsplash. <https://unsplash.com/photos/candy-lot-c7Z4vQoelQk>

Unsplash. (2020, March 12). *Photo by Michał Parzuchowski on Unsplash*. Beautiful Free Images & Pictures |

Unsplash. <https://unsplash.com/photos/white-and-orange-medication-pill-7TWRwDjfGew>

Unsplash. (2020, January 7). *Photo by museums Victoria on Unsplash*. Beautiful Free Images & Pictures |

Unsplash. <https://unsplash.com/photos/grayscale-photo-of-woman-using-headphones-TVe0IEdsVc8>

Unsplash. (2021, November 12). *Photo by Elsa Olofsson on Unsplash*. Beautiful Free Images & Pictures |

Unsplash. https://unsplash.com/photos/a-bag-of-cereal-and-a-bag-of-weed-sitting-on-a-table-et_-4E_hXNI

Unsplash. (2021, May 1). *Photo by iMattSmart on Unsplash*. Beautiful Free Images & Pictures | Unsplash. [https://unsplash.com/photos/2-](https://unsplash.com/photos/2-silver-round-coins-on-white-wooden-table-flYfzIWe7Kc)

[silver-round-coins-on-white-wooden-table-flYfzIWe7Kc](https://unsplash.com/photos/2-silver-round-coins-on-white-wooden-table-flYfzIWe7Kc)

Unsplash. (n.d.). *Marbles*. Beautiful Free Images & Pictures | Unsplash. <https://unsplash.com/s/photos/marbles>